


A. T. HADIDI  
A. F. AZMY  
Editors

# Hypospadias Surgery

An Illustrated Guide



Springer

# Thiersch-Duplay Principle

Moneer Hanna, Adam C. Weiser

## Introduction

In 1869, Professor C. Thiersch reported that in 1857 and 1858 he had tubularized the urethral plate to form a urethral canal in a child born with epispadias. He credited the technique to August Brauser, his onetime assistant. Thiersch's classic article illustrated the design of the flaps and the asymmetric lateral incisions so that the urethral suture lines are unopposed. In 1874, Duplay described the tubularization of the urethral plate distal to the urethral orifice. His first successful hypospadias repair with this technique was achieved in five stages. In 1880, Duplay observed the capacity of the urethral plate to tubularize over a catheter. He wrote; "Although the catheter is not actually covered entirely by skin, I am convinced that this has no ill effect on the formation of the new urethra; stricture formation does not occur so long as half of the urethral wall is supplied by skin". This concept was popularized by Denis Browne in 1949, when he described the buried skin strip method for hypospadias repair.

Mettauer first reported the concept of skin chordee in 1842, and subsequently D.R. Smith reported it in 1967. In 1968 Allen and Spence utilized the technique of degloving the penile skin and performed foreskin transposition to correct coronal hypospadias with moderate to severe chordee. King (1970) incorporated the concepts of Mettauer and Thiersch-Duplay to correct midshaft hypospadias and brought the meatus to the coronal sulcus.

In early years glanular and subcoronal hypospadias were often not repaired, because the complications of repair often overshadowed the benefits of surgical correction. Duckett's (1981) meatal advancement and glanuloplasty technique (MAGPI) was designed to reduce the risks of formal urethroplasty in distal hypospadias. Time and experience demonstrated that this technique could not be universally applied to all patients with distal hypospadias. Arap et al. (1984) modified the MAGPI technique to repair a more proximal meatus. Decter (1991) described the technique of an "M inverted V" glanuloplasty and utilized the Mathieu (1932) principle. Both Arap's and Decter's methods were designed to reduce the chance of meatal retraction, which is sometimes seen after conventional MAGPI repair, and to improve the cosmetic result of the glans penis. However, neither achieved wide acceptance.

Zaontz, in 1989, applied the Thiersch-Duplay principle to the repair of distal hypospadias. He reported excellent results with the glans approximation procedure (GAP). The operation was indicated for patients with coronal or glanular hypospadias, deep glanular groove, and a fish-mouth meatus. The GAP eliminated the ventral glanular tilt, meatal retraction and splaying of the urinary stream that was seen at times in meatal advancement and glanuloplasty procedures. Van Horn and Kass (1995) modified King's (1970) approach by extending the paraurethral incision to the tip of the glans penis and used a two layer ventral closure of the glans penis. They found that very few children were not candidates for this technique of glanuloplasty and in situ tubularization for the repair of distal hypospadias. They achieved better cosmetic results than with either the Mathieu or the MAGPI procedure.

In 1997 Stock and Hanna reported the largest documented series of Thiersch-Duplay repairs. Combining the principles of Heineke-Mikulicz meatoplasty to widen the meatus dorsally at 12 o'clock with Thiersch-Duplay tubularization of the urethral plate, they noted a low complication rate of 2.1% in 512 children.

While some were embracing the Thiersch-Duplay principle, others looked to the meatal-based flap technique of Mathieu, which also uses the urethral plate as the dorsal wall of the urethra. In 1969, Barcat modified the Mathieu technique, using apposing epithelial flaps based at the meatus to create a neourethra and dissecting the urethral plate from its bed. He then incised the glans penis and placed the urethral tube within the newly created sulcus. With the Barcat technique the configuration of the glans or meatus did not matter. However, the post-operative incidence of fistulae (15-20%) somewhat dampened the enthusiasm for this technique (Redman 1987). Koff et al. (1994) modified the Barcat technique and interposed a second layer of tissue over the neourethra, thus reducing the fistula rate to 2%. Koff noted that the only contraindication for this technique was in cases where a large amount of chordee was caused by factors distal to the hypospadiac meatus, whereby transection of the urethral plate was required. Barthold et al. reported their experience with 295 cases in 1996. All of these surgical modifications, including the Mathieu technique, share the inherent potential complications of raising and rotating a random skin flap.

Midline incision of the urethral plate was first reported by Reddy in 1975. He performed the incision to excise "fibrous tissue" in the midline that he believed to be the cause of the chordee. He then combined this with the Thiersch-Duplay principle and tubularized the urethral plate. Rich et al. (1989) described a technique for the creation of a normal vertical slit-like meatus by hinging the distal urethral plate longitudinally in the midline. This modification was applied to a variety of meatal-based flaps and achieved excellent cosmetic results. In 1994 Snodgrass reported on the technique of a tubularized incised plate urethroplasty (TIP) for distal hypospadias. A deep sagittal incision of the urethral plate was made from the meatus to the tip of the glans penis. This incision facilitates tubularization of the plate and results in a normal slit-shaped meatus. Furthermore, the deep incision prevents tension on the ventral suture line, thus acting as an internal relaxing incision. Hinging allows the urethral plate to be tubularized even when its width would ordinarily be inadequate to construct a neourethra of sufficient caliber.

We find the Thiersch-Duplay procedure offers several advantages. It utilizes the tissues that were embryonically destined to form a urethra; there is minimal disturbance of the blood supply of the urethral plate, which is often well vascularized, there is hardly any contracture of the tubularized plates, and stricture formation is indeed a rare complication.

### **Preoperative Evaluation**

A routine urologic history is taken and physical examination conducted. Questions regarding maternal prenatal history and family history of hypospadias are also asked.

On physical examination one notes the position of the urinary meatus and quality of the perimeatal skin, the depth of the glanular groove, presence and degree of chordee, penile torsion, penoscrotal transposition and whether the child has been circumcised. The presence or absence and location of the testicles are recorded, and if undescended testicle is diagnosed in conjunction with any degree of hypospadias, intersex workup is requested.

In children with proximal and especially in perineoscrotal hypospadias, voiding cystography is recommended, as we encountered a significantly large prostatic utricle in approximately 25% of children. We also encountered vesicoureteral reflux in 15% of the patients we studied (unpublished data).

We currently perform surgery when the patient is 6 months old. In the child with a small phallus, 50 mg of testosterone is given intramuscularly 3-4 weeks preoperatively.

## Patient Selection

We began using the Thiersch-Duplay principle in 1987 for children with a meatus at or just proximal to the coronal sulcus. When the meatus was stenotic, or a prominent shelf was encountered, we performed a Heineke-Mikulicz meatoplasty at 12 o'clock. Our experience in 512 consecutive cases was reported previously (Stock and Hanna 1997). We have subsequently extended the use of the Thiersch-Duplay technique to proximal hypospadias with chordee due to skin tethering or mild chordee ( $<30^\circ$ ), due to corporal disproportion, which was corrected by the Nesbit (1967) procedure of tunica albuginea placcation (TAP) (Daskalopoulos et al. 1993). Early in our series the absence of a deep glanular groove and/or the presence of hypoplastic thin skin at the urinary meatus were considered contraindications to the Thiersch-Duplay technique. The addition of the Reddy-Rich-Snodgrass incision of the urethral plate and distally in the glans penis allowed for repair of hypospadias in children with a shallow or minimal glanular groove.

Currently in our practice, the only contraindication to the Thiersch-Duplay repair is the presence of moderate or severe ventral chordee of  $>30^\circ$ , due to corporal disproportion. In such cases we divide the urethral plate and place a dermal graft to lengthen the ventral wall of the corpora, rather than shorten the dorsal walls by the Nesbit or the TAP procedure.

## Operative Management

A 5/0 silk stay suture is placed in the glans penis dorsal to where the future meatus will be. If the meatus is stenotic a longitudinal midline incision is made at 12 o'clock. This incision is closed transversely in a Heineke-Mikulicz fashion with interrupted 7-0 polyglycolic suture (Fig. 13.1.1a). An 8-F feeding tube is inserted in the urethra. If the perimeatal skin is thin and hypoplastic an incision is made ventrally until healthy skin is seen. The incised skin edges are then approximated with interrupted 7-0 polyglycolic sutures (Fig. 13.1.2). A subcoronal incision is made dorsally, laterally and ventrally around the meatus; the width of the urethral plate is 12 mm, leaving 2 mm of skin around the meatus (Fig. 13.1.1b, c). The skin and dartos fascia are dissected circumferentially proximally and the penis is degloved. In some cases deep dissection of the penoscrotal junction is necessary to completely straighten the penis. An artificial erection test is performed by placing a vessel loop as a tourniquet around the base of the penis, then injecting the corpora with normal saline. In the case of residual mild curvature  $<30^\circ$ , we used to use the Nesbit procedure or TAP modification. However, we have recently adopted the Baskin et al. (1998) method for chordee repair. If the glanular groove is deep, we find it unnecessary to incise the glans penis on either side and prefer to denude the skin by excising two wedges of glanular skin on either side, similar to the GAP (Fig. 13.1.3). If the glanular groove is inadequately shallow, we incise the glans penis in the midline at 12 o'clock to avoid any tension on the ventral suture line. The feeding tube is then removed and either a Silastic urethral catheter or a silicone splint of appropriate size is placed and secured. The urethral plate is then tubularized over the catheter using a running subcuticular 7-0 polydioxanone suture (PDS) (Fig.13.1.1d). A dartos flap is raised, mobilized from the dorsal penile skin, then rotated and sutured to cover the urethral suture line. The glanular skin is approximated with horizontal mattress interrupted 7-0 polyglycolic sutures (Fig. 13.1.1e). For resurfacing the penis we often adopt Byars flaps (1955), which create a midline ventral raphe. However, the available skin and its blood supply dictate the final closure (Fig. 13.1.1f). Duoderm dressing is applied around the penis and secured with Op.site transparent adhesive. The catheter drains into a double diaper and the child is discharged the same day. In distal hypospadias repair a catheter is seldom used, but for proximal repairs the catheter and dressing are necessary and are removed 3-5 days postoperatively. Prolonged urinary drainage is frequently associated with catheter obstruction and bladder spasm, which only serve to complicate matters.

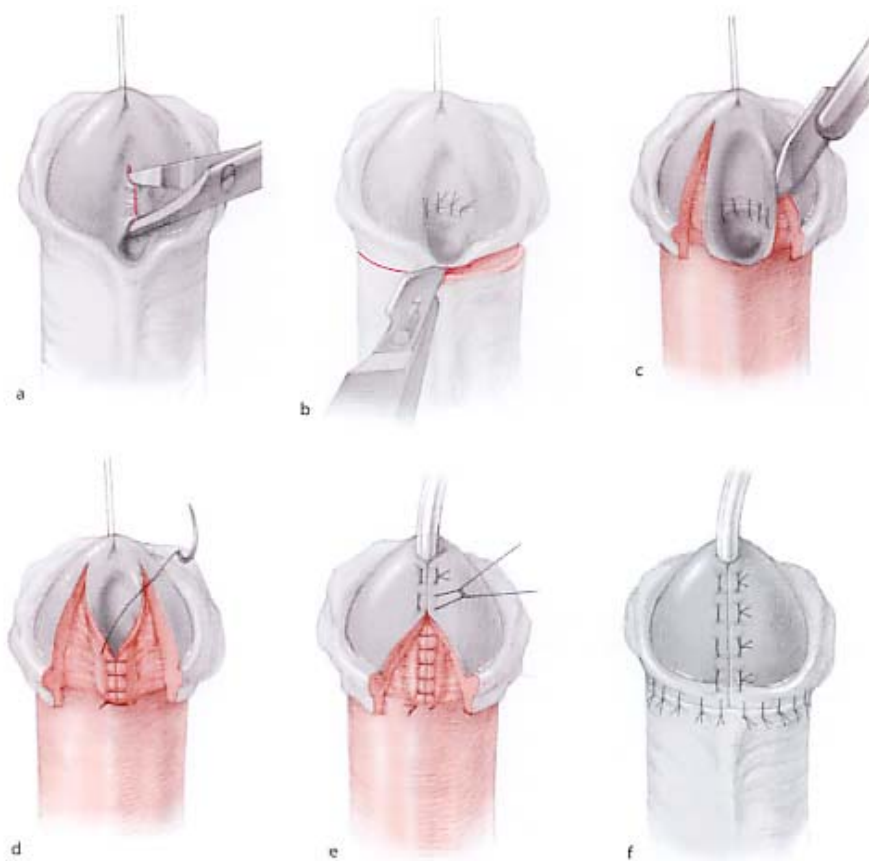


Fig. 13.1.1a-f. Diagrammatic illustration of the Thiersch-Duplay repair of distal hypospadias. a) A longitudinal midline incision is made at 12 o'clock. This incision is closed transversely in Heineke-Mikulicz fashion. b) A subcoronal incision is made around the glans penis. c) An incision is made dorsally, laterally and ventrally around the meatus; the width of the urethral plate is 12 mm, leaving 2 mm of skin around the meatus. d) The urethral plate is tubularized over the catheter using a running suture. e) The glanular skin is approximated with horizontal mattress interrupted 7-0 polyglycolic sutures. f) The available skin and its blood supply dictate the final closure.

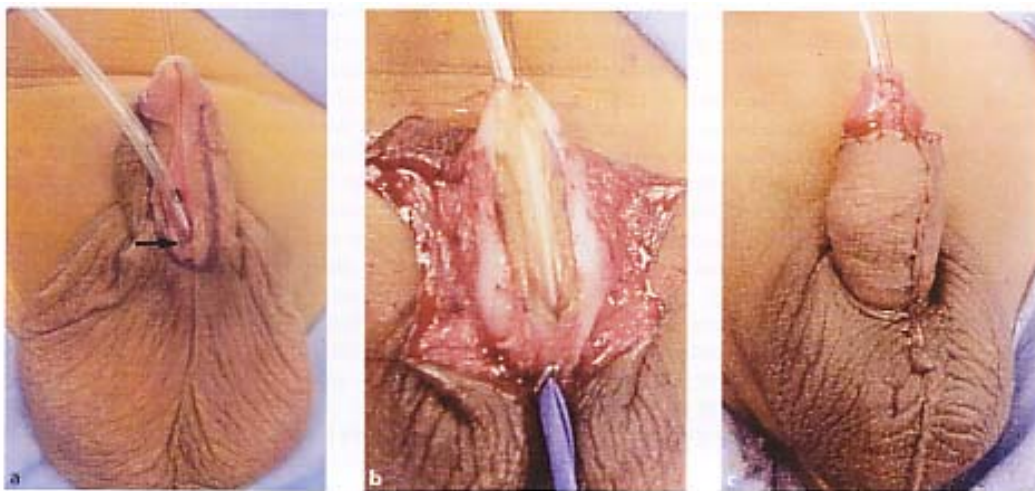


Fig. 13.1.2a-c. Thiersch-Duplay repair of proximal hypo- and denudation of glanular skin on either side of deep glaspadias. a) Penoscrotal hypospadias and hypoplastic meatal nular groove. c) Completed repair: the suture line is covered skin: ventral meatoplasty at 6 o'clock. b) Lateral skin incisions with dartos flap prior to skin closure.

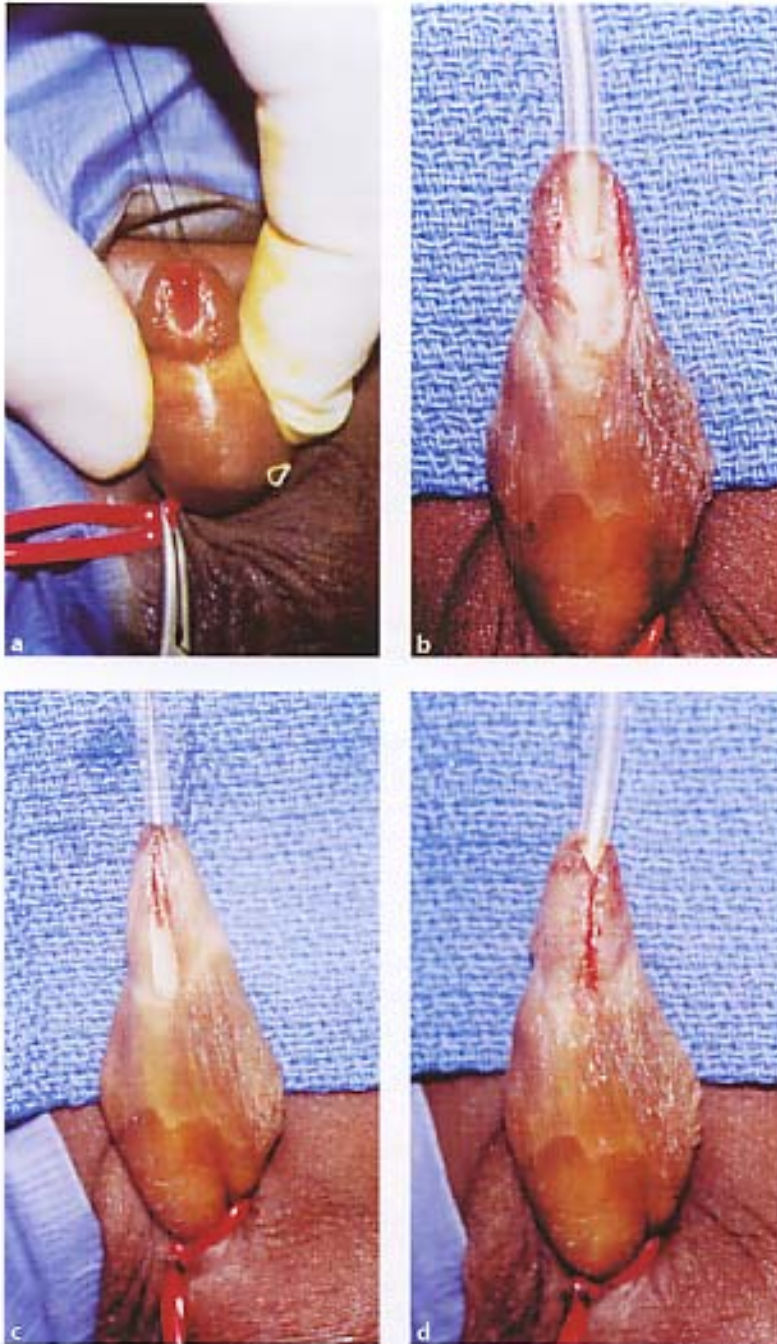


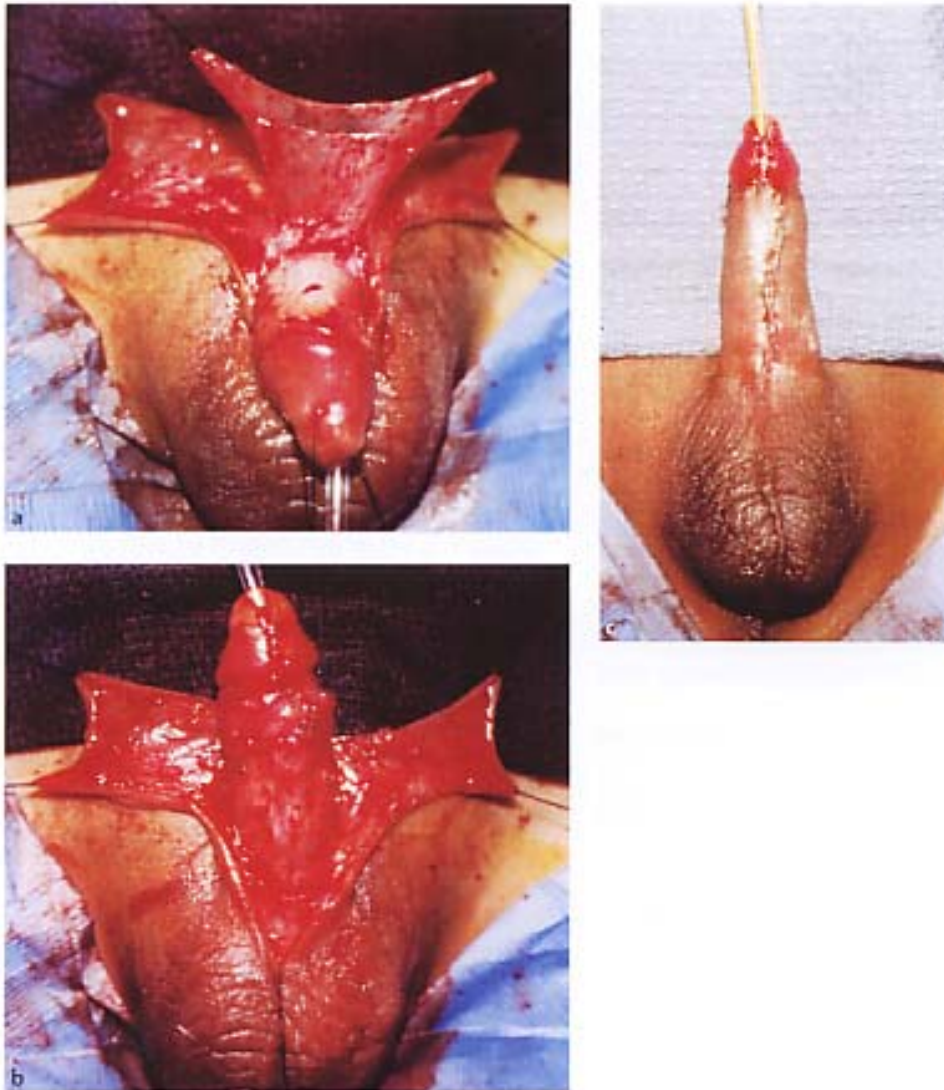
Fig. 13.1.3a-d. GAP procedure. a) Megameatus with deep sutures. Note placement of ventral stay sutures aligns the groove. b) Glanular skin is excised on either side. c) The tissues. d) Skin closure using horizontal mattress sutures urethral plate is tubularized using continuous subcuticular./

## Results

The Thiersch-Duplay principle with or without hinging of the urethral plate is now widely accepted and practiced by many surgeons.

The main complications in the reported series are urethrocutaneous fistula and stricture formation. Table 13.1.1 summarizes the surgical morbidity in the largest reported series of cases using the Thiersch-Duplay principle. It is inevitable that there are subtle variations of the surgical technique, and these are hard to quantify. However, in our experience the major factors that determine success and complications are primary vs reoperative repair, and distal vs proximal hypospadias. In comparing our early series (1987-1994), which included 512 children with distal hypospadias (coronal or juxtacoronary meatus), with our second series of 265 children with proximal hypospadias (penile, midshaft and penoscrotal meatus), it became apparent that surgical complications were more often encountered (8.6%) in proximal than in distal repairs (2.9%).

The interposition of a healthy de-epithelialized skin flap, as described by Durham Smith (1973), reduces the incidence of urethrocutaneous fistula. We often raise a dartos flap from the dorsal penile skin and rotate it to cover the ventral urethral suture line (a Fig. 13.1.4).



**Table 13.1.1.** Surgical morbidity in the major reported series of patients operated on using the Thiersch-Duplay principle.

Reference	Number of patients	Primary vs secondary repair	Location	Complications ----- ----- Meatal stenosis	Fistula
Zaontz 1989: GAP	24	Primary	Coronal 11, proximal 13	0	1
Kass 2000: glanuloplasty (no hinging)	308	Primary	Coronal/glans 84%, midshaft 9%, prox./peno-scrotal 7%	Diverticulum 2 (0.6%)	28 (9.1%): distal 6.2%, mid. 17.9%, proximal 42.9%
Snodgrass et al. (1996)	148	Primary	Distal	3	Fistula 5, glans dehiscence 3
Ross and Kay (1997)	18	Primary 15, secondary 3	Distal or midshaft	0	0
Stock and Hanna (1997)	512	Primary	Distal	2	Initial 5 (4 small fistulae diagnosed after toilet training)
Steckler and Zaontz (1997)	33	Primary	Distal 31, midshaft or proximal 2	0	0
Snodgrass et al. (1998)	27	Primary	Midshaft, penoscrotal	1	Fistula 1, glans dehiscence 1
Stock and Hanna (1997)	265	Primary	Midshaft to proximal, penoscrotal	Stricture 3, diverticulum 2	Fistula 16, dehiscence 2
Decter and Franzoni (1998)	197 (156 hinged)	Primary	Glans 52, coronal 101, proximal 44	Meatal retraction 4	Fistula 5
Dayanc et al. (2000)	25	Primary 23, secondary 2	Distal 20, midshaft 11	Mid-penile 1 (primary), distal 1 (primary)	Distal 1 (secondary)
Hayashi et al. (2001)	13	Secondary	Distal 5	0	Distal 1 (secondary)
Shanberg et al. (2001)	13	Secondary	Distal	1	Fistula + glans dehiscence 1
Smith (2001)	64	Primary	Distal 53, midshaft 11	0	0
Yang et al. (2001)	25	Secondary	Distal 10, midshaft 9, proximal 4, penoscrotal 2	13 (3 in patients with unaltered urethral plate and no preoperative fistula)	7 (0 in patients with unaltered urethral plate and no preoperative fistula)

## Conclusions

Hypospadias surgery provides ample opportunity for modification by any surgeon who wishes to establish his individuality. Some authors claim originality of idea, but it behooves us all to credit those who pioneered current surgical concepts and principles, thus preserving our surgical



heritage. We submit that the Thiersch-Duplay principle represents the basic foundation for all the surgical methods that utilize the urethral plate to construct a urethral tube.

## References

- Allen TD, Spence HM: The surgical treatment of coronal hypospadias and related problems. *J Urol.* 1968; 100: 504.
- Arap S, Mitre AI, de Goes GM: Modified meatal advancement and glanuloplasty repair of distal hypospadias. *J Urol.* 1984;131:1140.
- Barcat J: L'hypospadias. III. Les urethroplasties, les resultats -les complications. *Ann Chir Infant.* 1969; 10:310.
- Barthold JS, Tell TL, Rodman JF: Modified Barcat balanic groove technique for hypospadias repair: experience with 295 cases. *J Urol.* 1996; 155:1735.
- Baskin LS, Erol A, Li YW, et al: Anatomical studies of hypospadias. *J Urol.* 1998; 160:1108.
- Browne D: An operation for hypospadias. *Proc. R Soc. Med.* 1949; 41:466.
- Byars LT: A technique for consistently satisfactory repair of hypospadias. *Surg Gynecol Obstet.* 1955; 100:184.
- Daskalopoulos BI, Baskin L, Duckett JW, et al: Congenital penile curvature (chordee without hypospadias). *Urology.* 1993; 42:708.
- Dayanc M, Tan MO, GoKalp A, et al: Tubularized incised plate urethroplasty for distal and mid penile hypospadias. *Eur Urol.* 2000; 37:102-125.
- Decter RM: M inverted V glansplasty: a procedure for distal hypospadias *J Urol.* 1991; 146:641.
- Decter RM, Franzoni DF: Distal hypospadias repair by the modified Thiersch-Duplay technique with or without hinging the urethral plate: A near ideal way to correct distal hypospadias. *J Urol.* 1998; 162:1156.
- Duckett JW: MAGPI (meatal advancement and glanuloplasty): a procedure for subcoronal hypospadias. *Urol Clin North Am.* 1981; 8:513.
- Duplay S: De l'hypospadias perineo-scrotal et de son traitement chirurgical. *Arch Gen Med.* 1874; 1:613:657.
- Duplay S: Sur le traitement chirurgical de l'hypospadias et de l'epispadias. *Arch Gen Med.* 1880; 5:257.
- Hayashi Y, Kojima Y, Mizuno K, et al: Tubularized incisedplate urethroplasty for secondary hypospadias surgery. *Int J Urol.* 2001; 8:444-448.
- Kass EJ, Chung AK: Glanuloplasty and in situ tubularization of the urethral plate: Long-term follow up. *J Urol.* 2000; 164: 991.
- King LR: Hypospadias - a one stage repair without skin graft based on a new principle: chordee is sometimes produced by skin alone. *J Urol.* 1970; 103:660.
- Koff SA, Brinkman J, Ulrich J, et al: Extensive mobilization of the urethral plate and urethra for repair of hypospadias: the modified Barcat technique. *J Urol.* 1994; 151: 466.
- Mathieu P: Traitement en un temps de l'hypospadias balanique et juxta-balanique. *J Chir (Paris).* 1932; 39:481.
- Mettauer JP: Practical observations on those malformations of the male urethra and penis, termed hypospadias and epispadias with an anomalous case. *Am J Med Sci.* 1842; 4:43.
- Nesbit RM: Operation for correction of distal penile ventral curvature with or without hypospadias. *J Urol.* 1967; 97: 470.
- Reddy LN: One stage repair of hypospadias. *Urology* 1975; 5:475.
- Redman JF: The Barcat balanic groove technique for the repair of distal hypospadias. *J Urol.* 1987; 137:83.
- Rich MA, Keating MA, Snyder HM III, et al: Hinging the urethral plate in hypospadias meatoplasty. *J Urol.* 1989; 142:1551.
- Ross JH, Kay R: Use of de-epithelialized local skin flap in hypspadias repairs accomplished by tubularization of the incised urethral plate. *Urology* 1997; 50:110.
- Shanberg AM, Sanderson K, Duel B: Re-operative hypospadias repair using the Snodgrass incised plate urethroplasty. *BJU Int.* 2001; 87:544-547
- Smith DR: Repair of hypospadias in the pre-school child. A report of 150 cases. *J Urol.* 1967; 97:723.
- Smith ED: A de-epithelised overlap flap technique in the repair of hypospadias. *Br J Plast Surg.* 1973; 26:106.
- Smith DP: A comprehensive analysis of a tubularized incised plate hypospadias repair. *Urology.* 2001; 57:778.

- Snodgrass W: Tubularized, incised plate urethroplasty for distal hypospadias. J Urol. 1994; 151:464.
- Snodgrass W, Koyle M, Manzoni G, et al: Tubularized incised plate hypospadias repair: Results of a multicenter experience. J Urol. 1996; 156:839.
- Snodgrass W, Keys M, Manzoni G, et al: Tubularized incised plate hypospadias repair for proximal hypospadias. J Urol. 1998; 159:2129.
- Steckler RN, Zaontz MR: Stent free Thiersch-Duplay hypospadias repair with the Snodgrass modification. J Urol. 1997; 158:1178.
- Stock JA, Hanna MK: Distal urethroplasty and glanuloplasty procedures: Results of 512 repairs. Urology. 1997; 49:449.
- Thiersch C: fiber die Entstehungsweise and operative Behandlung des Epispadie. Arch Heilkd. 1869; 10:20.
- Van Horn AC, Kass FJ: Glanuloplasty and in situ tubularization of the urethral plate: simple reliable technique for the majority of boys with hypospadias. J Urol. 1995; 154:1505.
- Zaontz MR: The GAP (glans approximation procedure) for glanular/coronal hypospadias. J Urol. 1989; 141:359.